



This is a peer-reviewed, post-print (final draft post-refereeing) version of the following published document, ©2023 and is licensed under Creative Commons: Attribution-Noncommercial-No Derivative Works 4.0 license:

Pan, Daniel, Atkinson, Barry, Decker, Jonathan ORCID logo
ORCID: <https://orcid.org/0000-0001-5904-7311>, Williams, Caroline M, Nazareth, Joshua, Martin, Christopher A, Bird, Paul, Fahad, Muhammad, Nicholls, Ian, Spencer, Antony, Onianwa, Okechukwu, Vogt, Alexander, Sahota, Amandip, Tang, Julian W, Stephenson, Iain, Bennett, Allan M, Pareek, Manish and Barer, Michael R (2023) Concomitant, consecutive, self-obtained facemask and swab samples from exhaled breath, pox lesions, nasopharynx and the face in patients recovering from mpox - a longitudinal sampling study. *Journal of Infection*, 87 (5). pp. 459-461. doi:10.1016/j.jinf.2023.05.007

Official URL: <http://doi.org/10.1016/j.jinf.2023.05.007>

DOI: <http://dx.doi.org/10.1016/j.jinf.2023.05.007>

EPrint URI: <https://eprints.glos.ac.uk/id/eprint/13070>

Disclaimer

The University of Gloucestershire has obtained warranties from all depositors as to their title in the material deposited and as to their right to deposit such material.

The University of Gloucestershire makes no representation or warranties of commercial utility, title, or fitness for a particular purpose or any other warranty, express or implied in respect of any material deposited.

The University of Gloucestershire makes no representation that the use of the materials will not infringe any patent, copyright, trademark or other property or proprietary rights.

The University of Gloucestershire accepts no liability for any infringement of intellectual property rights in any material deposited but will remove such material from public view pending investigation in the event of an allegation of any such infringement.

PLEASE SCROLL DOWN FOR TEXT.

Journal Pre-proof

Concomitant, consecutive, self-obtained facemask and swab samples from exhaled breath, pox lesions, nasopharynx and the face in patients recovering from mpox – a longitudinal sampling study

Daniel Pan
Barry Atkinson
Jonathan Decker
Caroline M Williams
Joshua Nazareth, Christopher A Martin
Paul Bird
Muhammad Fahad
Ian Nicholls, Antony Spencer, Okechukwu Onianwa
Alexander Vogt, Amandip Sahota
Julian W Tang
Iain Stephenson
Allan M Bennett
Manish Pareek
Michael R Barer



PII: S0163-4453(23)00286-4

DOI: <https://doi.org/10.1016/j.jinf.2023.05.007>

Reference: YJINF5962

To appear in: *Journal of Infection*

Accepted date: 6

Please cite this article as: Daniel Pan, Barry Atkinson, Jonathan Decker, Caroline M Williams, Joshua Nazareth, Christopher A Martin, Paul Bird, Muhammad Fahad, Ian Nicholls, Antony Spencer, Okechukwu Onianwa, Alexander Vogt, Amandip Sahota, Julian W Tang, Iain Stephenson, Allan M Bennett, Manish Pareek and Michael R Barer, Concomitant, consecutive, self-obtained facemask and swab samples from exhaled breath, pox lesions, nasopharynx and the face in patients recovering from mpox – a longitudinal sampling study, *Journal of Infection*, (2023) doi:<https://doi.org/10.1016/j.jinf.2023.05.007>

This is a PDF file of an article that has undergone enhancements after acceptance, such as the addition of a cover page and metadata, and formatting for readability,

but it is not yet the definitive version of record. This version will undergo additional copyediting, typesetting and review before it is published in its final form, but we are providing this version to give early visibility of the article. Please note that, during the production process, errors may be discovered which could affect the content, and all legal disclaimers that apply to the journal pertain.

© 2023 Published by Elsevier.

Concomitant, consecutive, self-obtained facemask and swab samples from exhaled breath, pox lesions, nasopharynx and the face in patients recovering from mpox – a longitudinal sampling study

Daniel Pan^{1,2,3,4}, Barry Atkinson⁵, Jonathan Decker¹, Caroline M Williams^{1,6}, Joshua Nazareth^{1,2,3}, Christopher A Martin^{1,2,3}, Paul Bird^{1,6}, Muhammad Fahad², Ian Nicholls⁵, Antony Spencer⁵, Okechukwu Onianwa⁵, Alexander Vogt², Amandip Sahota², Julian W Tang^{1,6}, Iain Stephenson², Allan M Bennett⁵, Manish Pareek^{1,2,3}, Michael R Barer^{1,3,6}

¹Department of Respiratory Sciences, University of Leicester

²Department of Infectious Diseases and HIV Medicine, University Hospitals of Leicester NHS Trust

³NIHR Leicester Biomedical Research Centre

⁴Li Ka Shing Institute for Health Information and Discovery, University of Oxford

⁵Research and Evaluation, UK Health Security Agency, Porton Down, UK

⁶Department of Microbiology, University Hospitals of Leicester NHS Trust

Word count: 1037

Dear Editor,

Mellon and colleagues reported mpox virus (MPXV) DNA in air samples from a hospital room dedicated to mpox-infected patients.¹ However, longitudinal analysis of serial self-taken samples, collected contemporaneously from the same patient with mpox, have not been well described. Such data would help clinicians and policymakers to understand how long infected patients may continue to emit virus following infection, and through which route. We therefore performed a prospective longitudinal analysis of patients with mpox, with differing clinical severities of infection.

Participants were those with a confirmed diagnosis of mpox, under the care of the regional infectious diseases unit. Participants consented to provision of serial self-collected samples from the nasopharyngeal tract, face, and exhaled breath. For detection of MPXV DNA in exhaled breath, participants were asked to wear a modified duckbilled facemask (Integrity® 600–3004) containing two 1×9 cm 3D printed polyvinyl-alcohol (PVA) sampling matrix strips placed horizontally across the inside of the mask. Participants wore the mask for two hours continuously; no special behaviour was required, aside from not eating (see previous studies).^{2,3} In addition, we asked participants to provide longitudinal sampling of one pox lesion site. All samples were taken at the same time-point, twice a day (once in the morning and once in the afternoon), on a daily basis for six days, when the patient was self-isolating in their own home. Thus, each participant collected up to 8 samples on a daily basis for this study. Swab samples were processed and analysed by RT-qPCR as previously described; exposed facemask strips were processed similarly but using a QIAvac manifold (Qiagen) to allow analysis of all sample material.⁴ The study had ethical approval from the West Midlands Research Ethics Committee (REC Reference 20/WM/0152) and was conducted in accordance with ICH-GCP, Declaration of Helsinki and Data Protection Act 1998 and NHS Act 2006. Both study participants gave written, informed consent.

Participant 1 was a 25-year-old MSM, who was HIV positive but well controlled on Dolutegravir/Abacavir/Lamivudine (Triumeq), who developed pox lesions on his forehead, fingers, feet, hands and hair 31 days prior to sampling. Although he initially had systemic symptoms of fever, malaise and swollen cervical lymph nodes, this had settled by the time of sampling. He had also received one dose of the smallpox vaccine 28 days prior to sampling. Participant 1 felt systemically well at time of sampling, apart from crusted lesions in his hands, from which he provided swab samples. Participant 1 lived alone.

Participant 2 was a 22-year-old MSM, with no medical issues. He developed a sore throat, and pox lesions 17 days prior to sampling. At the time of sampling, he was systemically unwell, reporting swollen eyes, swollen throat, fevers and drenching night sweats. Active pox lesions were present within his throat and on his body. He did not receive the smallpox vaccine and lived in a large house with his family throughout his illness, none of whom reported any symptoms in the months following his infection.

From 22nd August to 20th September 2022, a total of 72 samples were collected from these two participants (Figure 1). Participant 1 (*mild* mpox) provided a total of 36 samples from 31 days post symptom onset. Patient 2 (*moderate* mpox) provided a total of 36 samples from day 17 post symptom onset. Participant 1 had the highest DNA MPXV loads (lowest RT-qPCR Ct values) in the pox lesions from his hands (panel D), which decreased over the course of the next six days, but with large fluctuations in MPXV DNA levels between consecutive days (for example, change in Ct value of around 24 to around 34 over 12 hours) possibly due to non-standardised lesion swabbing by the patient. MPXV DNA was also detectable in the nasopharynx and on the face although much lower in quantity (panels A and B). Exhaled MPXV DNA was detectable in trace amounts throughout the study period (panel D). Participant 2, whilst highly symptomatic during the course of sampling, had variable detection of MPXV DNA over the course of sampling from all sites in very small quantities (Ct value 34 or more; panels A-D).

Our small longitudinal study of two participants had three main findings. Firstly, we demonstrate that it was possible to capture exhaled MPXV DNA, although in small quantities, using self-taken, unsupervised facemask sampling. In previous studies, using the same method of sampling we have demonstrated an association between quantity of

exhaled SARS-CoV-2, and tuberculosis bacilli and household transmission.^{3,5} Whilst small quantities of exhaled MPXV DNA found in this study aligns with existing epidemiological studies on mpox transmission dynamics, it is difficult to ascertain whether aerosol transmission was possible, since sampling occurred late in illness.^{6,7} Of note, none of participant 2's household were infected despite living in the same house as the index case since symptom onset.

Secondly, MPXV DNA was detectable in respiratory samples as well as large quantities within crusted pox lesions up to 31 days after symptoms initially begun. This is the longest duration of respiratory sample positivity reported in the literature so far; previously the longest duration in upper respiratory tract samples was three weeks, reported prior to the current outbreak.^{8,9} Furthermore, the presence of high levels of DNA within a crusted lesion goes against the classical teaching for poxviruses, where infected patients were thought to have low levels of DNA when their lesions had crusted over.¹⁰

Finally, we found that disease severity did not appear to associate with MPXV DNA in our samples. Whether prolonged shedding of MPXV DNA within different sites, quantity of MPXV DNA within pox lesions or a lack of association with active infection within our study was due to one of our participants being HIV positive (although well controlled) is unknown, and requires further study.

In conclusion, within this longitudinal study on serially collected samples in acute mpox cases of differing severity, we conclude that DNA MPXV loads collected from a swab of a crusted pox lesion, face, nasopharynx and exhaled breath using facemask sampling appear to be independent of active disease severity and can be detected for as long as 31 days after symptom onset, when the patient is almost fully recovered. Future studies must

investigate whether transmission of mpox can occur long after initial infection, especially in HIV positive individuals.

References

1. Mellon G, Rubenstein E, Atoine M *et al.* Air detection of monkeypox virus in a dedicated outpatient clinic room for monkeypox infection diagnosis. *Journal of Infection* 2023; **86**(3): p256-308
2. Williams CM, Pan D, Decker J *et al.* Exhaled SARS-CoV-2 quantified by face-mask sampling in hospitalised patients with COVID-19. *Journal of Infection* 2021; **82**(6): p253-259
3. Pan D, Williams CM, Decker J *et al.* Exhaled SARS-CoV-2 RNA viral load kinetics measured by facemask sampling associates with household transmission. *Clinical Microbiology and Infection* 2023; **29**(2): p254 E1-254, E6
4. Gould S, Atkinson B, Okechukwu O *et al.* Air and surface sampling for monkeypox virus in a UK hospital: an observational study. *The Lancet Microbe* 2022; **3**(12):e904-e911
5. Williams CM, Muhammad AK, Sambou B *et al.* Exhaled Mycobacterium tuberculosis predicts incident infection in household contacts. *Clinical Infectious Diseases* 2023; **8**;76(3):e957-e964
6. Lapa D, Carletti F, Mazzotta V *et al.* Monkeypox virus isolation from a semen sample collected in the early phase of infection in a patient with prolonged seminal viral shedding. *The Lancet Infectious Diseases* 2022; **22**(22): 1267-1269

7. Endo A, Murayama H, Abott S *et al.* Heavy-tailed sexual contact networks and monkeypox epidemiology in the global outbreak. *Science* 2022; **378**(6615);90-94
8. Pan D, Nazareth J, Sze S *et al.* Transmission of monkeypox/mpox virus: a narrative review of environmental, viral, host and population factors in relation to the 2022 international outbreak. *Journal of Medical Virology* 2023;e28534
9. Adler H, Gould S, Hine P *et al.* Clinical features and management of human monkeypox: a retrospective observational study in the UK. *The Lancet Infectious Diseases* 2022; **22**L1153-1162
10. Kaler J, Hussain A, Flores G *et al.* Monkeypox: a comprehensive review of transmission, pathogenesis and manifestation. *Cureus* 2022;**14**(7):26531

Figure legend

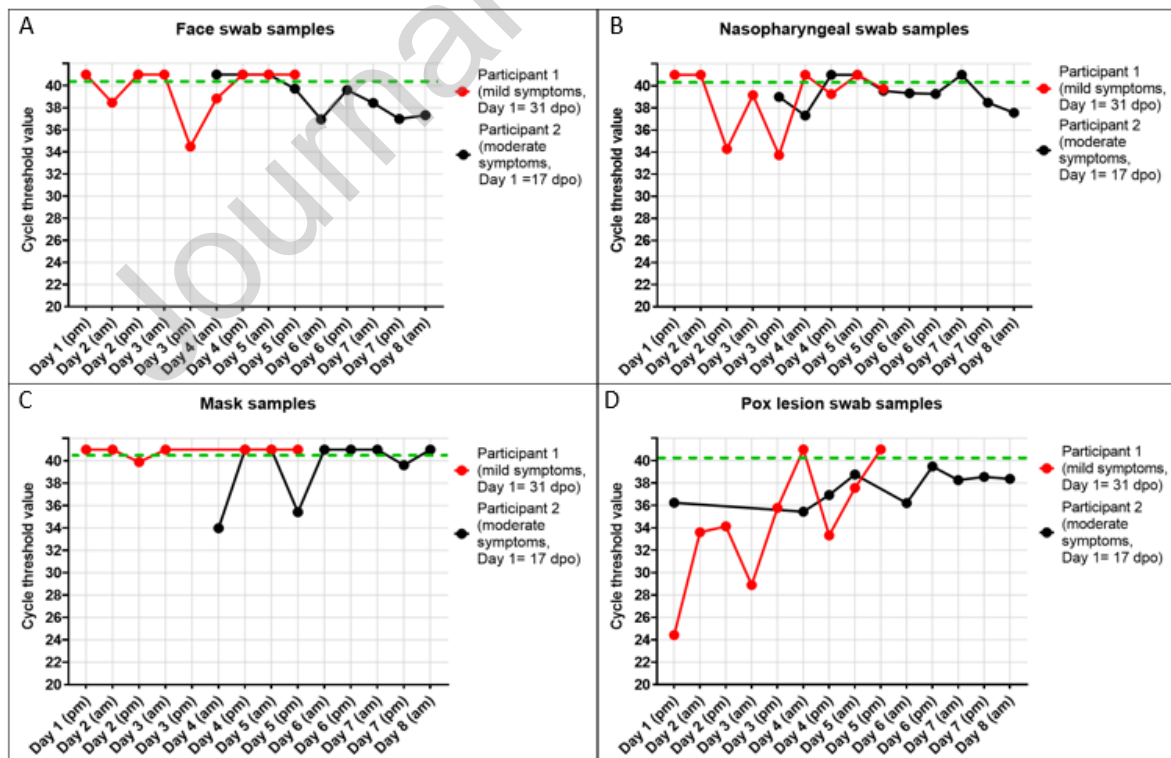


Figure 1: Relative MPXV viral loads indicated by calculated cycle threshold values.

Acknowledgements

Daniel Pan is supported by a NIHR Doctoral Research Fellowship (NIHR302338)

Declaration of Competing Interest

The authors have no conflicts of interests to declare.

Journal Pre-proof