



This is a peer-reviewed, final published version of the following document and is licensed under Creative Commons: Attribution 4.0 license:

Scanlon, Peter H ORCID logoORCID: <https://orcid.org/0000-0001-8513-710X>, Norridge, Charlotte F. E., Donachie, Paul H. J. and Mohamed, Quresh (2022) Should we still be performing macular laser for non-centre involving diabetic macular oedema? Results from a UK centre. *Eye*, 36 (3). pp. 646-648. doi:10.1038/s41433-021-01789-3

Official URL: <http://dx.doi.org/10.1038/s41433-021-01789-3>

DOI: <http://dx.doi.org/10.1038/s41433-021-01789-3>

EPrint URI: <https://eprints.glos.ac.uk/id/eprint/10295>

Disclaimer

The University of Gloucestershire has obtained warranties from all depositors as to their title in the material deposited and as to their right to deposit such material.

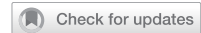The University of Gloucestershire makes no representation or warranties of commercial utility, title, or fitness for a particular purpose or any other warranty, express or implied in respect of any material deposited.

The University of Gloucestershire makes no representation that the use of the materials will not infringe any patent, copyright, trademark or other property or proprietary rights.

The University of Gloucestershire accepts no liability for any infringement of intellectual property rights in any material deposited but will remove such material from public view pending investigation in the event of an allegation of any such infringement.

PLEASE SCROLL DOWN FOR TEXT.

BRIEF COMMUNICATION OPEN



Should we still be performing macular laser for non-centre involving diabetic macular oedema? Results from a UK centre

Peter H. Scanlon^{1,2,3}, Charlotte F. E. Norridge¹, Paul H. J. Donachie¹ and Quresh Mohamed¹

© The Author(s) 2021

Eye; <https://doi.org/10.1038/s41433-021-01789-3>

BACKGROUND

The Early Treatment Diabetic Retinopathy Study [1] (ETDRS) showed that focal photocoagulation of “clinically significant” diabetic macular oedema (CSMO) substantially reduced the risk of visual loss. Vascular Endothelial Growth Factor (VEGF) inhibitor drugs have subsequently been shown to have better results for centre involving diabetic macular oedema [2].

METHODS

A retrospective analysis of first macular laser treatment was conducted between 01/01/2010 and 31/12/2019 and OCT measurements from the same machine, within 3 months before and 1–12 months after treatment in the Gloucestershire Eye Unit. Eyes were excluded if their central subfield retinal thickness (CRT) was ≥ 400 microns, they had ocular co-pathologies

or surgery in the previous 6 months. ETDRS grid areas described by Soliman [3] were used to assess the results of laser treatment (Fig. 1).

RESULTS

Eligible for analysis were 316 eyes from 275 patients with 175 male, 246 T2DM, and median age 63.1 years. A total of 8 consultants treated 198 (62.7%) eyes, 5 specialty doctors treated 101 (32.0%) eyes and 11 trainees treated 17 (5.4%) eyes with 2 consultants treating >50 eyes. The laser machine used was a PASCAL green laser (Topcon UK) for 271 (85.8%) eyes. The median number of burns administered to an eye was 24 (IQR; 15–34). Burn durations of 0.02 or 0.05 s were used for 69.3% of eyes. For 311 (98.4%) eyes the beam diameter was 100 microns.

A total of 253 eyes had Zeiss Cirrus OCT measurements (Table 1), mean baseline CRT 303.6 microns, mean follow-up CRT 305.1 microns and mean difference $+1.5$ microns (95% CI: -4.8 to $+7.7$). In only two macular regions did $<50\%$ of eyes have a reduction in thickness. A total of 63 eyes had Heidelberg OCT measurements, mean baseline CRT 302.4 microns, mean follow-up CRT 309.4 microns and mean difference $+7.0$ microns (95% CI: -4.7 to $+18.8$). In all macular regions $>50\%$ of eyes had a reduction in thickness.

After VEGF inhibitor injections became available in 2013, only 3 (5.4%) eyes with Heidelberg and 10 (10.5%) eyes with Zeiss OCT measurements received injections within 1 year of laser.

The median baseline and follow up Visual Acuity (VA) were both 0.20 LogMAR.

DISCUSSION

The Diabetic Retinopathy Clinical Research Network (DRCRN) [4] compared two laser techniques in 2007 that had OCT data available on 213 eyes at 12 months post laser. They found, in both treatment groups, a reduction of central retinal thickening, weighted inner zone thickening, and retinal volume with no significant change in visual acuity outcomes.

As the NICE guidelines [5] in England do not recommend treatment until the central subfield retinal thickness (CRT) is ≥ 400 microns, macular laser treatment was assessed for predominantly non-centre involving diabetic macular oedema.

Macular laser treatment can be effective in reducing retinal thickening in the inner and outer parafoveal zones and in different macular regions with stable VA. Only 5.1% of eyes went on to

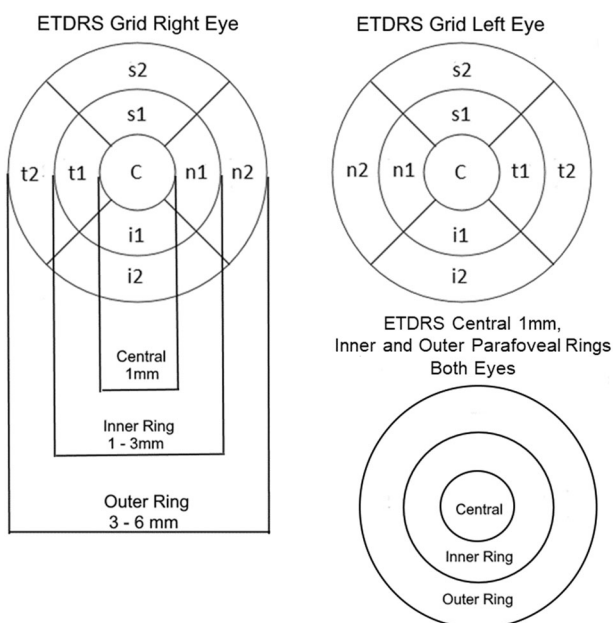


Fig. 1 Early treatment diabetic retinopathy study (ETDRS) grid areas. ETDRS grid right eye, ETDRS grid left eye, ETDRS central 1 mm, inner and outer parafoveal rings both eyes.

¹Gloucestershire Retinal Research Group, Gloucestershire Hospitals NHS Foundation Trust, Cheltenham General Hospital, Cheltenham, UK. ²Nuffield Department of Clinical Neuroscience, University of Oxford, Oxford, UK. ³University of Gloucestershire, Cheltenham, UK. ✉email: p.scanlon@nhs.net

Received: 29 March 2021 Revised: 28 July 2021 Accepted: 22 September 2021

Published online: 21 October 2021

Table 1. Macular Thickness estimates for 253 eyes assessed using a Zeiss Cirrus OCT machine and 63 eyes assessed using the Heidelberg OCT machine.

Macular thickness (μm)	Baseline mean (microns)	Follow-up mean (microns)	Mean difference ^a (microns)	95% CI ^b (microns)	Reduction n (%)	No change n (%)	Increase n (%)
Zeiss Cirrus (N = 253 unless ^c)							
Macular region							
Temporal t1	352.0	347.4	-4.6	-10.028 to 0.732	147 (58.1)	6 (2.4)	100 (39.5)
Superior s1	353.6	347.2	-6.4	-10.542 to -2.296	141 (55.7)	7 (2.8)	105 (41.5)
Inferior i1	337.8	337.5	-0.3	-4.358 to 3.765	126 (49.8)	13 (5.1)	114 (45.1)
Nasal n1	338.6	337.8	-0.8	-5.262 to 3.570	138 (54.5)	12 (4.7)	103 (40.7)
Temporal t2 ^c	311.2	304.3	-6.8	-11.616 to -2.019	138 (57.3)	5 (2.1)	98 (40.7)
Superior s2 ^c	310.8	306.9	-3.6	-7.281 to -0.007	142 (56.8)	2 (0.8)	106 (42.4)
Inferior i2 ^c	296.0	294.6	-1.7	-5.756 to 2.346	114 (46.7)	17 (7.0)	113 (46.3)
Nasal n2 ^c	310.9	309.9	-1.0	-4.270 to 2.343	127 (51.6)	14 (5.7)	105 (42.7)
ETDRS circle							
ETDRS 1 mm (Central C)	303.6	305.1	1.5	-4.750 to 7.659	130 (51.4)	7 (2.8)	116 (45.8)
Inner parafoveal ring (1-3 mm)	1,382.0	1,369.8	-12.2	-24.399 to -0.020	149 (58.9)	1 (0.4)	103 (40.7)
Outer parafoveal ring (3-6 mm) ^c	1,226.1	1,212.7	-12.6	-22.288 to -2.900	134 (58.5)	0 (0.0)	95 (41.5)
Mean Cube average thickness ^c	306.4	303.5	-2.9	-5.626 to -0.175	144 (57.4)	5 (2.0)	102 (40.6)
Mean total macular volume	11.0	10.9	-0.1	-0.211 to -0.022	142 (56.1)	15 (5.9)	96 (37.9)
Heidelberg (N = 63 unless ^c)							
Macular region							
Temporal t1	356.2	359.4	3.2	-5.063 to 11.444	33 (52.4)	1 (1.6)	29 (46.0)
Superior s1	368.2	366.9	-1.3	-7.954 to 5.351	37 (58.7)	2 (3.2)	24 (38.1)
Inferior i1	354.9	357.8	2.9	-5.912 to 11.721	36 (57.1)	0 (0.0)	27 (42.9)
Nasal n1	357.2	355.8	-1.4	-8.302 to 5.477	37 (58.7)	6 (9.5)	20 (31.7)
Temporal t2	328.6	326.3	-2.3	-9.020 to 4.416	36 (57.1)	2 (3.2)	25 (39.7)
Superior s2	330.2	333.7	3.5	-9.750 to 16.844	36 (57.1)	0 (0.0)	27 (42.9)
Inferior i2 ^c	322.6	318.3	-4.6	-11.981 to 2.833	37 (60.7)	2 (3.3)	22 (36.1)
Nasal n2	333.4	332.1	-1.3	-6.239 to 3.572	33 (52.4)	5 (7.9)	25 (39.7)
ETDRS circle							
ETDRS 1 mm (Central C)	302.4	309.4	7.0	-4.733 to 18.764	29 (46.0)	0 (0.0)	34 (54.0)
Inner parafoveal ring (1-3 mm)	1,436.6	1,439.9	3.4	-22.173 to 28.935	36 (57.1)	0 (0.0)	27 (42.9)
Outer parafoveal ring (3-6 mm) ^c	1,312.8	1,308.7	-4.7	-27.937 to 18.575	40 (63.6)	0 (0.0)	21 (34.4)
Mean total macular volume	9.5	9.4	-0.1	-0.215 to 0.080	18 (28.6)	19 (30.2)	26 (41.3)

^aNegative values indicate reduction in thickness and positive values increase in thickness.

^b95% Confidence Interval for the mean difference in measurements between baseline and follow up.

^cDue to OCT machines not being able to measure all regions some eyes have missing values. Zeiss Cirrus assessed eyes; for the temporal t2 region (n = 248 at baseline, 244 at follow up and 241 for difference). For the superior s2 region (n = 252 at baseline, 251 at follow up and 250 for difference). For the inferior i2 region (n = 247 at baseline, 250 at follow up and 244 for difference). For the nasal n2 region (n = 249 at baseline, 250 at follow up and 246 for difference). For the outer parafoveal ring (n = 239 at baseline, 241 at follow up and 229 for difference). For the mean cube average (n = 252 at baseline, 251 at follow up and 251 for difference). Heidelberg assessed eyes; for the inferior i2 region (n = 62 at baseline, 61 at follow up and 61 for difference). For the outer parafoveal ring (n = 62 at baseline, 61 at follow up and 61 for difference).

require injections with VEGF inhibitors within 12 months of the initial laser. This study provides evidence that there is still a place for macular laser treatment in non-centre involving diabetic macular oedema.

REFERENCES

1. Photocoagulation for diabetic macular edema. Early Treatment Diabetic Retinopathy Study report number 1. Early Treatment Diabetic Retinopathy Study research group. *Arch Ophthalmol.* 1985 Dec;103:1796–806. PubMed PMID: 2866759.
2. Diabetic Retinopathy Clinical Research N, Wells JA, Glassman AR, Ayala AR, Jampol LM, Aiello LP, et al. Aflibercept, bevacizumab, or ranibizumab for diabetic macular edema. *N Engl J Med.* 2015;372:1193–203. PubMed PMID: 25692915. PubMed Central PMCID: PMC4422053.
3. Soliman W, Sander B, Soliman KA, Yehya S, Rahamn MS, Larsen M. The predictive value of optical coherence tomography after grid laser photocoagulation for diffuse diabetic macular oedema. *Acta Ophthalmol.* 2008;86:284–91. PubMed PMID: 18005220.
4. Writing Committee for the Diabetic Retinopathy Clinical Research N, Fong DS, Strauber SF, Aiello LP, Beck RW, Callanan DG, et al. Comparison of the modified Early Treatment Diabetic Retinopathy Study and mild macular grid laser photocoagulation strategies for diabetic macular edema. *Arch Ophthalmol.* 2007;125:469–80. PubMed PMID: 17420366. eng.
5. NICE. Aflibercept for treating diabetic macular oedema. Technology appraisal guidance [TA346] 2015. Available from: <https://www.nice.org.uk/guidance/ta346/chapter/1-guidance>.

ACKNOWLEDGEMENTS

We are grateful for accurate data entry performed by Yan Li and Grace Blazey. No financial support was received for this work.

AUTHOR CONTRIBUTIONS

PHS has written the initial draft of the paper and updated subsequent drafts following comments from the co-authors. CFEN conducted the first analysis of the data and has contributed to all drafts of the paper. PHJD conducted the second

analysis of the data and has contributed to all drafts of the paper. QM has contributed to all drafts of the paper.

STATEMENT OF ETHICS

The Gloucestershire Hospitals NHS Foundation Trust (GHNHSFT) Research Governance processes did not require ethics approval but required us to register this audit with the GHNHSFT Quality Improvement team with the Registration no. SG200709. Informed consent was not required.

COMPETING INTERESTS

PHS has received consulting fees from Boehringer and Bayer and speaker fees from Novartis.

ADDITIONAL INFORMATION

Correspondence and requests for materials should be addressed to Peter H. Scanlon.

Reprints and permission information is available at <http://www.nature.com/reprints>

Publisher's note Springer Nature remains neutral with regard to jurisdictional claims in published maps and institutional affiliations.



Open Access This article is licensed under a Creative Commons Attribution 4.0 International License, which permits use, sharing, adaptation, distribution and reproduction in any medium or format, as long as you give appropriate credit to the original author(s) and the source, provide a link to the Creative Commons license, and indicate if changes were made. The images or other third party material in this article are included in the article's Creative Commons license, unless indicated otherwise in a credit line to the material. If material is not included in the article's Creative Commons license and your intended use is not permitted by statutory regulation or exceeds the permitted use, you will need to obtain permission directly from the copyright holder. To view a copy of this license, visit <http://creativecommons.org/licenses/by/4.0/>.

© The Author(s) 2021