



UNIVERSITY OF  
GLOUCESTERSHIRE

This is a peer-reviewed, post-print (final draft post-refereeing) version of the following published document, © American Diabetes Association (ADA). This is an author-created, un-copyedited electronic version of an article accepted for publication in 'Diabetes'. The American Diabetes Association (ADA), publisher of 'Diabetes', is not responsible for any errors or omissions in this version of the manuscript or any version derived from it by third parties. The definitive publisher-authenticated version will be available in a future issue of 'Diabetes' in print and online at: <http://diabetes.diabetesjournals.org/lookup/suppl/doi:10.2337/db16-1453/-/DC1> and is licensed under All Rights Reserved license:

**Santos, Ana Rita, Ribeiro, Luísa, Bandello, Francesco, Lattanzio, Rosangela, Egan, Catherine, Frydkjaer-Olsen, Ulrik, García-Arumí, José, Gibson, Jonathan, Grauslund DMSci, Jakob, Harding, Simon P, Lang, Gabriele E, Massin, Pascale, Midená, Edoardo, Scanlon, Peter H ORCID: 0000-0001-8513-710X, Aldington, Stephen J, Simão, Sílvia, Schwartz, Christian, Ponsati, Berta, Porta, Massimo, Costa, Miguel Ângelo, Hernández, Cristina, Cunha-Vaz, José and Simó, Rafael (2017) Functional and Structural Findings of Neurodegeneration in Early Stages of Diabetic Retinopathy. Cross-sectional Analyses of Baseline Data of the EUROCONDOR project. *Diabetes*, 66 (9). pp. 2503-2510. doi:10.2337/db16-1453**

Official URL: <https://doi.org/10.2337/db16-1453>  
DOI: <http://dx.doi.org/10.2337/db16-1453>  
EPrint URI: <http://eprints.glos.ac.uk/id/eprint/4743>

#### **Disclaimer**

The University of Gloucestershire has obtained warranties from all depositors as to their title in the material deposited and as to their right to deposit such material.

The University of Gloucestershire makes no representation or warranties of commercial utility, title, or fitness for a particular purpose or any other warranty, express or implied in respect of any material deposited.

The University of Gloucestershire makes no representation that the use of the materials will not infringe any patent, copyright, trademark or other property or proprietary rights.

The University of Gloucestershire accepts no liability for any infringement of intellectual property rights in any material deposited but will remove such material from public view pending investigation in the event of an allegation of any such infringement.

PLEASE SCROLL DOWN FOR TEXT.

**Title: Functional and Structural Findings in Early Stages of Diabetic Retinopathy. Cross-sectional analyses of the baseline data of the EUROCONDOR project.**

**Short running title: Cross-sectional analyses of the baseline results of the EUROCONDOR project**

Ana Rita Santos MSc<sup>1</sup>, Luísa Ribeiro MD<sup>1</sup>, Francesco Bandello MD<sup>2</sup>, Rosangela Lattanzio MD<sup>2</sup>, Catherine Egan MD<sup>3</sup>, Ulrik Frydkjaer-Olsen PhD<sup>4</sup>, José García-Arumí MD<sup>5</sup>, Jonathan Gibson MD<sup>6</sup>, Jakob Grauslund DMSci<sup>4</sup>, Simon P Harding MD<sup>7</sup>, Gabriele E Lang MD<sup>8</sup>, Pascale Massin MD<sup>9</sup>, Edoardo Midena MD<sup>10</sup>, Peter Scanlon MD<sup>11</sup>, Steve Aldington HND<sup>11</sup>, Sílvia Simão BSc<sup>1</sup>, Christian Schwartz<sup>1</sup>, Berta Ponsati PhD<sup>12</sup>, Massimo Porta MD<sup>13</sup>, Miguel Ângelo Costa MSc<sup>1</sup>, Cristina Hernández MD<sup>14</sup>, José Cunha-Vaz MD<sup>1\*</sup>, Rafael Simó MD<sup>14\*</sup>. The European Consortium for the Early Treatment of Diabetic Retinopathy (EUROCONDOR)

**Affiliation:**

1. Association for Innovation and Biomedical Research on Light and Image (AIBILI). Coimbra, Portugal
2. Department of Ophthalmology. University Vita-Salute. Scientific Institute San Raffaele. Milano, Italy
3. Moorfields Eye Hospital NHS Foundation Trust, Institute of Ophthalmology/University College London. London, UK
4. Department of Clinical Research, Research Unit of Ophthalmology, University of Southern Denmark. Denmark
5. Department of Ophthalmology. Vall d'Hebron University Hospital. Barcelona, Spain.
6. Department of Vision Sciences, Aston University. Birmingham, UK
7. Department of Eye & Vision Science, Institute of Ageing and Chronic Disease, University of Liverpool. Liverpool, United Kingdom
8. Department of Ophthalmology, University of Ulm. Ulm, Germany
9. Department of Ophthalmology, Lariboisière Hospital. Paris, France
10. Department of Ophthalmology, University of Padova. Padova, Italy
11. Gloucestershire Hospitals NHS Foundation Trust. Cheltenham, UK
12. BCN Peptides. Barcelona, Spain
13. Department of Medical Sciences, University of Turin. Turin, Italy
14. Diabetes and Metabolism Research Unit and CIBERDEM. Vall d'Hebron Research Institute. Barcelona, Spain

Corresponding authors\*

José Cunha-Vaz

Association for Innovation and Biomedical Research on Light and Image (AIBILI), Coimbra, Portugal.

Azinhaga de Santa Comba, Celas

3000-548 Coimbra, Portugal

e-mail: [cunhavaz@aibili.pt](mailto:cunhavaz@aibili.pt)

Rafael Simó

Diabetes and Metabolism Research Unit and CIBERDEM.

Vall d'Hebron Research Institute.

Pg. Vall d'Hebron 119-129, 08035 Barcelona, Spain

e-mail: [rafael.simo@vhir.org](mailto:rafael.simo@vhir.org)

## **Abstract**

The aim of this cross-sectional study is to evaluate the relationship between: a) the functional and structural measurements of neurodegeneration in initial stages of diabetic retinopathy (DR); b) the presence of neurodegeneration and early microvascular impairment. For this purpose baseline data of type 2 diabetic patients (n=449) enrolled in the EUROCONDOR study (NCT01726075) were analyzed. Functional studies were performed by multifocal ERG (mfERG) to evaluate neurodysfunction and structural measurements by Spectral Domain Optical-Coherence Tomography (SD-OCT) to evaluate neurodegeneration. The relationship between SD-OCT and mfERG was examined by superimposing the SD-OCT map of ganglion cell layer inner plexiform layer (GCL-IPL) over the central rings of mfERG. Among mfERG measurements, P1 amplitude was more sensitive than the implicit time (IT), and it was lower in patients with ETDRS 20-35 than in patients with ETDRS <20 (p=0.005). In 58% of cases, mfERG abnormalities were present in the absence of microangiopathic lesions in fundus photography. Regarding SD-OCT, GCL-IPL thickness was lower in diabetic patients than in control subjects but only 9% presented values below the normal range. Correspondence between SD-OCT thinning and mfERG abnormalities was shown in 67% of the eyes with ETDRS <20 and in 83% of the eyes with ETDRS 20-35. Notably, 32% of patients with ETDRS 20-35 presented no abnormalities in mfERG or SD-OCT. We conclude that there is a link between mfERG and SD-OCT measurements which increases with the presence of microvascular impairment. However, in our particular study population (ETDRS  $\leq$  35) a significant proportion of patients had normal GC-IPL thickness and normal mfERG characteristics. These findings open up the hypothesis that neurodegeneration could play a role in the pathogenesis of DR in a large proportion, but not in all type 2 diabetic patients.

Diabetic retinopathy (DR) is the commonest complication of diabetes and remains the leading cause of blindness among working-age individuals in most developed countries (1). Since the global incidence of diabetes is set to rise dramatically from an estimated 382 million people in 2013 to 592 million by 2030 (2), DR will become an even more serious problem in the coming years.

Tight control of blood glucose levels and blood pressure are essential in preventing DR development or arresting its progression. However, current treatments for DR are targeted at advanced stages when laser photocoagulation, intravitreal injections of anti-VGF agents or corticosteroids and vitreoretinal surgery are implemented. All these treatments are invasive, expensive, require a retinal specialist and have a significant number of secondary effects. Therefore, new treatments for the early stages of DR are needed (3, 4).

DR has been classically considered as a microvascular disease of the retina. However, growing evidence suggests that retinal neurodegeneration is an early event in the pathogenesis of DR, which could participate in the development of microvascular abnormalities (5-8). For this reason, it is reasonable to hypothesize that therapeutic strategies based on neuroprotection may be effective not only in preventing or arresting retinal neurodegeneration, but also in preventing the development and progression of the early stages of DR in terms of microvascular impairment (3, 8). This opens up the possibility of developing topical therapy in the early stages of DR, when currently established therapies such as laser photocoagulation or intravitreal injections of corticosteroids or anti-VEGF agents are inappropriate (8-10). EUROCONDOR (European Consortium for the Early Treatment of Diabetic Retinopathy) has been created in order to implement a large clinical trial (NCT01726075) using eye drops containing brimonidine or somatostatin (two previously demonstrated neuroprotective agents), in the early stages of diabetic retinal disease.

Multifocal electroretinography (mfERG) and spectral domain optical coherence tomography (SD-OCT) have both been employed in clinical studies to measure neurodysfunction and neurodegeneration. The mfERG has been shown to sensitively detect the presence of neuroretinal dysfunction in type 1 diabetic patients even without any detected blood-retinal barrier leakage measured by vitreous fluorometry (11). In addition, and more importantly, several authors have found that an increase of the implicit time (IT) in mfERG is a predictor for the development of visible vascular abnormalities over 1-year (12, 13), and 3-year periods (14). However, mfERG is cumbersome for the patient and time-consuming and, therefore, is only used in the setting of clinical trials. SD-OCT provides anatomical and structural information and is widely available, easy to perform and comfortable for the patients. However there is little information regarding the relationship between mfERG and SD-OCT and the presence of early microvascular impairment.

On this basis, the aim of the present work was to analyze the relationship between baseline mfERG characteristics and structural abnormalities assessed by SD-OCT, taking into account the degree of microvascular abnormalities in the early stages of DR.

## **Research Design and Methods**

### *Study Subjects*

The data for this cross-sectional study derived from the 449 type 2 diabetic patients with either no visible DR (ETDRS level <20) or only early stages of DR (ETDRS level 20-35) enrolled in the prospective, multicenter and randomized clinical trial EUROCONDOR (NCT01726075). This clinical trial was performed by 11 European ophthalmology clinical research centres of the European Consortium for the Early Treatment of Diabetic Retinopathy and funded by the European Commission 7<sup>th</sup> Framework Programme (Grant Agreement N: 278040).

In addition to ETDRS level  $\leq 35$ , the inclusion criteria were duration of diabetes for at least 5 years and age between 45-75 years. Exclusion criteria included previous laser photocoagulation, retinal degeneration-inducing diseases (i.e. glaucoma) and refractive error greater than or equal to  $\pm 5$  dioptre. Eyes with hazy ocular media or inadequate pupil dilatation that prevented good quality fundus photography were excluded. Patients with renal failure (creatinine  $> 123.76 \mu\text{mol/L}$ ) or A1C  $> 10\%$  ( $86 \text{ mmol/mol}$ ) in the previous 6 months were also excluded.

The study adhered to the tenets of the Declaration of Helsinki and was approved by the review boards of each participant country. Written informed consent was obtained from all patients before performing any procedures.

Each patient underwent a comprehensive ophthalmic examination, including a review of the medical history, best corrected visual acuity (BCVA) using ETDRS protocol, slit-lamp biomicroscopy, intraocular pressure measurement with Goldmann applanation tonometry, gonioscopy and dilated fundoscopic examination, and fasting blood sampling for blood count and biochemistry analysis. In addition, standardized 7 field color fundus photography (CFP), SD-OCT and mfERG were performed in all patients. These 3 examinations took place within the timeframe of one month and their outputs were graded by a centralized reading center (AIBILI CORC – Coimbra Ophthalmology Reading Center). Only one eye from each patient was included in the study. If both eyes met the inclusion criteria, one of the eyes was chosen randomly.

Grading data were analyzed in two groups according to ETDRS severity scale: patients with ETDRS level  $< 20$  (without microaneurysms), and patients with ETDRS level 20-35 (mild nonproliferative DR).

### *Multifocal ERG Recording and Analysis*

The mfERGs were recorded in the study eye using the RETI-port/scan 21 (Roland Consult, Berlin, Germany) visual electrophysiology system. Stimulation and recording of the mfERG responses were performed according to the International Society for Clinical Electrophysiology of Vision (ISCEV) guidelines (15, 16). After full dilation of the pupil with 1% tropicamide and 2,5% phenylephrine and topical anesthesia, a DTL-plus electrode was placed in the lower conjunctival fornix, a reference skin electrode was placed near the orbital rim and a ground skin electrode was attached in the forehead. The fellow eye was occluded and impedances were checked. The patient had to fixate a large red cross in the stimulation monitor and the fixation was controlled using a fundus camera and illumination with infrared light. The stimulus array consisted of 103 hexagons displayed at a 60-Hz frame rate and was centered on the fovea covering a visual field of 30°. The luminance of each hexagon was independently alternated between black (<2cd/m<sup>2</sup> of luminance) and white (200cd/m<sup>2</sup> of luminance) according to a pseudorandom binary m-sequence. Each recording was taken in 12 cycles of approximately 47 seconds each with an artefact rejection level of 10%. Exams on the baseline visit were rejected when they presented any of the following: (1) ‘eccentric fixation’; (2) ‘unsteady fixation’; and ‘too much noise compromising the waveform’. Sixty-four (64) exams had to be retaken. After the request, all exams were of sufficient quality to be included in the study cohort.

Data corresponding to P1 amplitude and IT of 103 hexagons, organized in 6 concentric rings (**Figure 1A**) obtained in type 2 diabetic patients were compared with a normative database (n= 111 healthy eyes from 76 non-diabetic age-matched controls) which was also generated in the setting of the EUROCONDOR project (17). Healthy volunteers recruited for the mfERG normative database were checked for diabetes by a revision of the medical history with recent blood analysis data. In addition, patients with any known ophthalmic disease were excluded from the study.

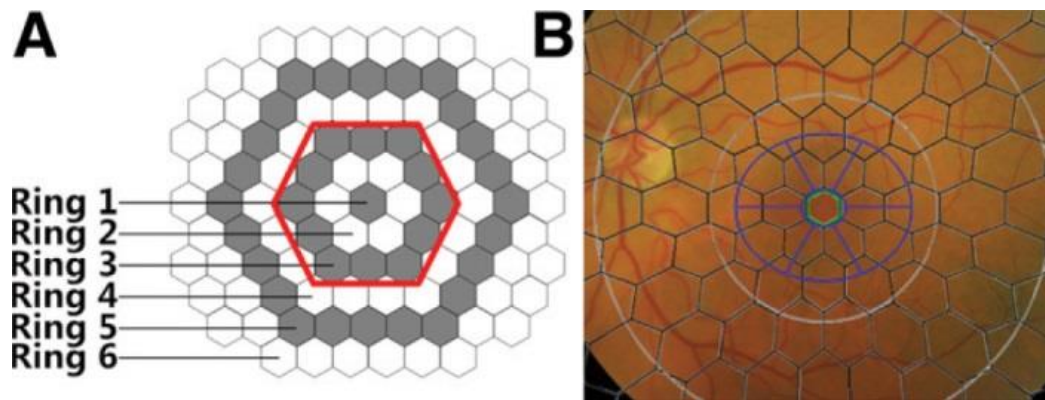


Figure 1 A and B

**Figure 1:** **A.** Diagram of the stimulus array used to elicit the multifocal ERGs. Stimulus consisted of 103 hexagons, organized in 6 concentric rings, scaled (not represented) to elicit similar amplitudes at all locations. **B.** Superimposition of the mfERG stimulus array and the SD-OCT GCL+IPL elliptical annulus grid (blue) on a fundus image, centered on the fovea. The green-contoured hexagon represents the central mfERG hexagon, and the two grey circles represent the 10° and 20° of the mfERG grid.

### *OCT Imaging and Analysis*

Spectral Domain OCT (SD-OCT) images were acquired by CIRRUS HD-OCT (Zeiss Meditec), henceforth designated as CIRRUS, or by Topcon 3D-OCT 2000 (Topcon Corporation), henceforth designated as Topcon, depending on the equipment available at each site, according to standardized acquisition protocols. A total of 284 patients underwent CIRRUS HD-OCT imaging (117 patients with ETDRS level <20 and 167 patients with ETDRS level 20-35), while 165 patients underwent Topcon 3D-OCT 2000 imaging (76 patients with ETDRS level <20 and 89 patients with ETDRS level 20-35). OCT scans were accepted upon confirmation of good quality and the absence of segmentation errors that compromised quantitative analysis. Thirteen exams had to be retaken. After the request all exams were of sufficient quality to be included in the study cohort.



Macular retinal thickness and macular GCL-IPL thickness were obtained from Macular Cube 512x128 acquisition of CIRRUS equipment and from 3D Macula 6mm x 6mm acquisition of Topcon, both acquired centered on fovea. Peripapillary RNFL thickness was obtained from CIRRUS using Optic Disc Cube acquisition and from Topcon using the 3D Disc 6.0mm x 6.0mm acquisition.

GCL-IPL and RNFL thicknesses obtained in type 2 diabetic patients were compared with normative databases of the respective equipment manufacturers. The normal RNFL values of the CIRRUS HD-OCT were calculated by determining the average value for a 62.5 years old person (the mean age of the population assessed with that equipment).

To account for differences between Topcon and CIRRUS equipment, mean values of macular thickness, macular GCL-IPL thickness and RNFL thickness at the optic disc were tested for each equipment. In order to address the differences, a conversion factor (mean CIRRUS value divided by mean Topcon value) was then multiplied for Topcon measurements (given that Topcon was used at only four sites). Conversion factors were 1.11, 1.20, and 0.93 for macular retinal thickness, macular GCL-IPL thickness, and RNFL thickness at the optic disc, respectively (18).

#### *Topographical coincidence between mfERG abnormalities and SD-OCT impairment*

By superimposing the OCT map of GCL-IPL over the mfERG hexagonal pattern (**Figure 1B**), we analysed the mfERG central rings: Ring 1, Ring 2 and Ring 3 (**Figure 1A, red-delimited area**). The P1 amplitude and IT were analyzed by the number of abnormal hexagons (an altered hexagon was defined as a hexagon with a z-score  $\geq 2$  for IT and  $\leq -2$  for amplitude). The relationship between the presence of abnormal hexagons and thinning of the GCL-IPL and RNFL layers was examined.

An eye with a central mfERG abnormality was defined as having at least one abnormal hexagon in any of the three central rings (**Figure 1**).

### *Statistical Analysis*

Descriptive statistics were calculated for all variables. Differences between normal values of mfERG amplitude and IT were inferred with one way analysis of variance (ANOVA). The correlation between mfERG or GCL-IPL/RNFL thickness parameters and age, diabetes duration and A1C was explored with multivariate logistic regression. The relationship between abnormalities in central mfERG parameters and thinning of GCL-IPL and/or RNFL was explored with chi-square test. Multiple comparison corrections (Bonferroni) were performed where indicated in the results section. Statistical analysis was performed with Stata 12.1 (StataCorp LP, College Station, TX, USA) and significance was set at 0.05.

## **Results**

### *General description*

Four hundred and forty-nine type 2 diabetic patients were included in this baseline analysis of the EUROCONDOR cohort. The main clinical characteristics of the patients, taking into account the ETDRS levels are displayed in **Table 1**.

**Table 1.** Demographic characteristics of study patients

	<b>Total</b> N=449	<b>ETDRS &lt;20</b> (n=193)	<b>ETDRS 20-35</b> (n=256)	<b>p*</b>
Age (years)	62.82±6.70	64.32±6.40	61.70±6.80	<0.001
Gender (% males)	65.9	70.5	62.5	n.s
Diabetes duration (years)	11.66±5.60	10.57±5.10	12.48±5.90	<0.001
Fasting blood glucose (mg/ml)	144±52	137±46	149±55	0.018
(mmol/L)	7.99±2.89	7.60±2.55	8.27±3.05	
A1C (%)	7.16±1.00	7.01±0.90	7.28±1.10	0.006
(mmol/mol)	(55±10.9)	(53±9.9)	(56±11.5)	
Hypertension (%)	73.3	73.1	73.4	n.s
Dyslipidemia (%)	70.8	74.1	68.4	n.s
Current smokers (%)	13.4	13.5	13.3	n.s
Microalbuminuria (%)	12.9	11.7	13.7	n.s
Cardiovascular disease (%)	20.3	22.3	18.8	n.s
BCVA letters Score	86.14±5.10	85.78±5.40	86.42±4.80	n.s

\* p value between ETDRS <20 and ETDRS 20-35

### *mfERG abnormalities*

Diabetic patients presented a significantly delayed IT from rings 3-6 ( $p < 0.001$ ) in comparison with age-matched non-diabetic control group (**Table 2**). We found no influence of ETDRS levels on P1 IT. Furthermore, the mean IT (ms) of the 6 rings was similar in type 2 diabetic patients with ETDRS level <20 or ETDRS level 20-35 ( $36.66 \pm 1.76$  vs.  $36.64 \pm 1.76$ ;  $p = n.s.$ ).

**Table 2.** Values of P1 implicit time and amplitude (mean±SD) of the six concentric rings in healthy controls and type 2 diabetic patients.

	Ring	Healthy controls (n=76)	ETDRS <20 (n=193)	ETDRS 20-35 (n= 256)	P*
<b>Implicit Time (ms)</b>	1	42.0±3.5	42.1±4.7	42.1±4.7	0.63
	2	36.0±2.0	36.6±2.9	36.6±2.8	0.08
	3	34.2±1.8 <sup>†</sup>	35.6±2.0	35.6±1.7	<0.001
	4	33.5±1.8 <sup>†</sup>	35.0±1.7	35.1±1.7	<0.001
	5	33.4±1.7 <sup>†</sup>	35.0±1.7	35.1±1.9	<0.001
	6	33.8±1.8 <sup>†</sup>	35.3±1.9	35.4±1.7	<0.001
<b>Amplitude (nV/deg<sup>2</sup>)</b>	1	128.9±26.4 <sup>†</sup>	118.4±40.1	111.5±35.8	<0.001
	2	70.2±13.3 <sup>†</sup>	56.3±16.1 <sup>‡</sup>	52.6±14.6 <sup>§</sup>	<0.001
	3	46.8±8.3 <sup>†</sup>	37.7±10.7 <sup>‡</sup>	34.5±9.1 <sup>§</sup>	<0.001
	4	32.6±5.7 <sup>†</sup>	26.7±8.1 <sup>‡</sup>	24.4±6.8 <sup>§</sup>	<0.001
	5	25.0±4.7 <sup>†</sup>	20.5±6.4 <sup>‡</sup>	18.8±5.5 <sup>§</sup>	<0.001
	6	20.3±4.0 <sup>†</sup>	16.3±5.4	15.3±5	<0.001

\* p value from ANOVA

<sup>†</sup> significantly different from ETDRS <20 and ETDRS 20-35

<sup>‡</sup> significantly different from Healthy controls and ETDRS 20-35

<sup>§</sup> significantly different from Healthy controls and ETDRS <20

The mean values of P1 amplitude were significantly lower in diabetic patients than in control group in all rings (all p<0.001), and the differences were even higher in patients with ETDRS level 20-35 than in patients without microangiopathic abnormalities (ETDRS <20) (**Table 2**). Thus, the mean amplitude (nV/deg<sup>2</sup>) was significantly higher in type 2 diabetic patients with

ETDRS <20 in comparison with those with ETDRS 20-35 ( $45.96 \pm 12.29$  vs.  $42.77 \pm 11.29$ ;  $p=0.006$ ).

The difference in P1 amplitude between central and peripheral retina (ring 1-ring 6) was significantly reduced in type 2 diabetic patients in comparison with non-diabetic subjects ( $99 \pm 35$  nV/deg<sup>2</sup> vs.  $109 \pm 26$  nV/deg<sup>2</sup> ;  $p < 0.001$ ).

Age was correlated with P1 IT ( $r=0.206$ ;  $p < 0.001$ ) and no relationship was found between P1 IT or amplitude with diabetes duration or A<sub>1C</sub> levels.

Finally, the 58% of diabetic patients with ETDRS <20 presented abnormalities in central mfERG, and this percentage increase to 66% in diabetic patients with ETDRS 20-35 ( $p=0.07$ ).

### ***SD-OCT abnormalities***

The average thickness of the macular GCL-IPL complex and the average thickness of the peripapillary RNFL were analyzed in the two DR study groups (ETDRS <20 and ETDRS 20-35) and compared with the normal thickness values given by the normative databases provided by the equipment manufacturers. The homogenized results obtained after applying the conversion factors previously mentioned are displayed in **Table 3**.

**Table 3.** SD-OCT abnormalities by DR severity level

	<b>Normal Values</b> N=282	<b>ETDRS &lt;20</b> N=193	<b>ETDRS 20-35</b> N=256	<b>All patients</b> N=449
<b>GCL-IPL (<math>\mu\text{m}</math>)</b>	82.1 $\pm$ 6.2	78.6 $\pm$ 7.3*	79.7 $\pm$ 7.7*	79.4 $\pm$ 7.3†
<b>RNFL (<math>\mu\text{m}</math>)</b>	89.8 $\pm$ 8.5	88.6 $\pm$ 10.3	89.9 $\pm$ 9.8	89.1 $\pm$ 9.7

\* Significantly different from Normal values on an independent samples t-test for  $p < 0.025$  (bonferroni correction for multiple comparisons)

† Significantly different from Normal values on an independent samples t-test for  $p < 0.05$ .

Data are mean $\pm$ SD

The average GCL-IPL thickness was significantly lower in diabetic eyes when compared to the normal population (79.4 $\pm$ 7.3  $\mu\text{m}$  vs. 82.1 $\pm$ 6.2  $\mu\text{m}$ ;  $p < 0.001$ ); but there was no difference among diabetics with different ETDRS levels (**Table 3**;  $p = \text{n.s.}$ ). Conversely, average RNFL at the optic disc presented no significant differences between diabetic eyes and the normal population (89.1 $\pm$ 9.7  $\mu\text{m}$  vs. 89.8 $\pm$ 8.5  $\mu\text{m}$ ;  $p = \text{n.s.}$ ). A total of 41 type 2 diabetic patients (9.1%) presented values of GCL-IPL or RNFL below the normal range.

We found that type 2 diabetic patients with ETDRS 20-35 presented values of GC-IPL thickness higher than patients with ETDRS 10 ( $p = 0.018$ ). However, when the crude data were corrected taking into account total retinal thickness no relationship between GCL-IPL thickness and ETDRS levels was found.

Age was negatively correlated with the average thicknesses of both GCL-IPL ( $r = -0.27$ ;  $p < 0.001$ ) and RNFL ( $r = -0.17$ ;  $p < 0.001$ ). However, no correlations were found between GCL-IPL or RNFL thickness and diabetes duration or HbA<sub>1C</sub> levels.

### ***Relationship between SD-OCT and mfERG***

In the 193 eyes classified as having ETDRS level <20 (with no apparent microvascular abnormalities), central mfERG abnormalities of amplitude or IT were present in 58% of eyes and there was a decrease below the normal values of GCL-IPL or RNFL layers thickness in only 9% of the eyes. Similarly, eyes with ETDRS levels 20-35 (with microvascular changes) (n=256) showed central mfERG abnormalities of amplitude or IT in 66% of the cases and thinning of GCL-IPL or RNFL in 9%.

The relationship between abnormalities in central mfERG parameters and thinning of GCL-IPL and/or RNFL is displayed in Table 4. In diabetic patients with ETDRS <20, 67% of the cases with GCL-IPL or RNFL thinning also presented mfERG abnormalities. However, in patients with ETDRS 20-35, 83% of the cases with GCL-IPL or RNFL thinning also presented mfERG abnormalities (p=0.07).

**Table 4.** Correspondence between abnormalities in central mfERG and SD-OCT parameters.

	<b>All patients (n=449)</b>		
	Normal mfERG	Abnormal mfERG	
	N (%)	N (%)	
Normal SD-OCT, n (%)	160 (35.6)	248 (55.2)	
Abnormal SD-OCT, n (%)	10 (2.2)	31 (6.9)	
			p= 0.06
	<b>ETDRS &lt;20 (n=193)</b>		
Normal SD-OCT, n (%)	76 (39.4)	99 (51.3)	
Abnormal SD-OCT, n (%)	6 (3.1)	12 (6.2)	
			p= 0.41
	<b>ETDRS 20-35 (n=256)</b>		
Normal SD-OCT, n (%)	84 (32.8)	149 (58.2)	
Abnormal SD-OCT, n (%)	4 (1.6)	19 (7.4)	
			p= 0.07

### **Relationship between measurements related to neurodegeneration and early microvascular impairment**

The relationship between the measurements related to neurodysfunction and/or neurodegeneration according to ETDRS levels are shown in Table 5. We found that 61% of diabetic patients with ETDRS <20 presented neurodysfunction/neurodegeneration and this proportion increased to 68% in patients with ETDRS 20-35 (Chi square: p=0.13). Therefore, neurodegeneration/neurodysfunction abnormalities did not significantly increase in presence of microvascular abnormalities but, as previously mentioned, this latter condition favored the clustering between mfERG and SD-OCT.



*Table 5. Relationship between the measurements related to neurodysfunction and/or neurodegeneration according to ETDRS levels*

	No Microangiopathy ETDRS <20 N=193			Microangiopathy ETDRS 20-35 N=256		
	No NRD	NRD		No NRD	NRD	
N (%)	75 (39)	118 (61)		82 (32)	174 (68)	
Age (years)	63.1±6.7	65.1±6.0	0.04	59.7±7.5	62.6±6.1	0.003
BMI (Kg/m <sup>2</sup> )	30	31	ns	30	30	ns
Diabetes duration (years)	11±5.5	10.3±4.8	ns	11.8±4.8	12.8±6.3	ns
Fasting blood glucose (mg/dL)	129±44	142±47	0.07	148±56	149±55	ns
(mmol/L)	7.16±2.44	7.88±2.61		8.21±3.11	8.27±3.05	
HbA1c (%)	7.05±0.79	6.98±0.96	ns	7.16±0.98	7.32±1.08	ns
(mmol/mol)	54 ±	53 ±		55 ±	56 ±	
Mean IT (ms)	36.16±1.41	36.96±1.88	0.001	35.93±1.41	36.98±1.81	<0.001
Mean A (nV/deg <sup>2</sup> )	51.35±11.11	42.56±12.89	0.012	48.61±9.00	40.12±11.22	<0.001
GCL-IPL (µm)	80.47±5.92	77.39±7.77	0.004	82.09±6.77	78.66±7.90	0.001
RNFL (µm)	90.70±9.17	87.35±9.67	0.018	92.18±8.31	88.22±10.28	0.003

NRD: neurodysfunction and/or neurodegeneration

It should be noted that 82 out of 256 patients with ETDRS 20-35 (32%) did not present any abnormalities in mfERG or SD-OCT examinations, thus suggesting the presence of primarily a microvascular or a microangiopathic phenotype. On the other hand 118 out of 193 patients (61%) without visible microvascular lesions (ETDRS<20) presented abnormalities related to neurodegeneration assessed by either mfERG (58%) or SD-OCT (9%), thus suggesting a neurodysfunctional or neurodegenerative phenotype.

## **Discussion**

The EUROCONDOR study was designed to test the potential role of two different neuroprotective agents in arresting the progression of retinal neurodegeneration in the diabetic retina. The major functional test chosen to identify and follow neurodegeneration was mfERG and structural abnormalities were evaluated by SD-OCT. In this report, the baseline data have been evaluated in order to study the relationship between neurodegeneration assessed by mfERG (functional abnormalities) and SD-OCT (structural damage), as well as their relationship with the absence (ETDRS level <20) or presence (ETDRS levels 20-35) of early microvascular retinal impairment.

Multifocal ERG is a highly sensitive method which allows for an objective and quantitative measurement of retinal function. When this technique is performed following a well-defined protocol by trained examiners, it offers reliable results, and may be particularly valuable for evaluating retinal neuron impairment. The baseline data collected from EUROCONDOR participants showed alterations of the mfERG in almost 60% of type 2 diabetic patients with no apparent fundus abnormalities (ETDRS level <20). These findings are in agreement with previous studies (11-14), and support the concept that functional impairment related to neurodegeneration is an early event in the diabetic retina. However, in 34% of type 2 diabetic patients with early microvascular impairment (ETDRS 20-35) mfERG abnormalities were not found. Therefore, it seems that in some type 2 diabetic patients, retinal neurodegeneration does not appear to play an essential role in the development of DR, at least when assessed by mfERG.

The most widely used mfERG parameter in the setting of diabetes has been the P1 IT because of its lower variability in comparison to P1 amplitude. However, our results provide evidence that P1 amplitude, rather than IT, is the most sensitive parameter. We found a decrease of P1 amplitude from the central to the peripheral retina (from ring 1 to ring 6) in both type 2 diabetic

patients and healthy controls. Our results agree with previous studies performed in Indian (19) and Japanese (20) normal subjects. The geographical distribution of cones (higher in the central retina and lower in the periphery) supports these findings (21, 22). Our results suggest that the difference in P1 amplitude from the central to the peripheral retina could be a useful parameter for monitoring the neurodegenerative process, but further studies to examine this issue are needed.

One important issue to be considered when analyzing mfERG is the fluctuations of the results that could occur depending on the glycemic excursions. In the present study, patients with poor glycemic control (HbA1c >10%) were excluded, the mean of fasting glucose was 7.99 mmol/L  $\pm$  SD 2.89, HbA1c was 7.1%  $\pm$  SD 1.0 (55 mmol/mol  $\pm$  SD 10.9) and, more importantly we did not observe any relationship between fasting glycemia or HbA1c levels with mfERG abnormalities. For all these reasons, a potential influence of glycemic fluctuations on mfERG seems very unlikely.

The most important structural damage of the retina detected by SD-OCT was a thinning of the GCL-IPL and RNFL layers, although in far fewer number of eyes/patients in comparison with mfERG abnormalities. However, mfERG abnormalities were absent in around 1/3 of patients with ETDRS level <20 in whom GCL-IPL or RNFL thickness were below the normal range. In this regard, it should be noted that mfERG is a measurement of cone photoreceptor and bipolar cell function (22), and may not represent inner retinal defects. Therefore, the observed dissociation between the two tests is not surprising. In addition, whereas the thinning of the neuroretina assessed by SD-OCT reflects neural loss, mfERG abnormalities could only be the consequence of neurodysfunction due to glial activation. This finding supports the complementarity of using both examinations when neurodysfunction/neurodegeneration is being assessed. One result that merits to be commented on is the absence of further GCL-IPL or RNFL thickness reduction when microangiopathy was detected, whereas P1 amplitude was

significantly reduced. In fact, an increase of GCL-IPL thickness was detected in patients with ETDRS 20-35 in comparison with patients with ETDRS <20. This could be attributed to the increased sensitivity of functional mfERG rather than structural SD-OCT abnormalities when assessing the neurodegenerative process. However, it is also possible that vascular leakage predominant in the Inner Nuclear layers (INL) in the initial stages of diabetic retinal disease leads to an increase in thickness of the retina, acting as a confounding factor. In a recent study, where a large cohort of diabetic eyes with non-proliferative retinopathy was followed for one year, thinning of GCL-IPL and RNFL was also found. But this increase in thinning was masked by the presence of retinal edema resulting from leakage from the retinal vessels and increase in the retinal extracellular space extending to the inner retinal layers (23). In this regard, in our study when the GCL-IPL thickness was corrected by taking into account total retinal thickness, the inverse relationship between GCL-IPL thickness and progression from ETDRS <20 to ETDRS 20-35 disappeared.

Both mfERG and SD-OCT abnormalities were related to age. This finding was expected due to the direct relationship between the neurodegenerative process and age. The lack of association between mfERG and SD-OCT measurements of neurodegeneration and A1C could be attributed to the well-established concept that A1C levels taken at a certain point in time do not necessarily represent the previous history of metabolic control of the patient and, therefore, biomarkers of long-term glycation might be more informative than A1C levels. In addition, the excellent control of blood glucose levels in this cohort (mean A1C = 7.16% [55.2 mmol/mol] and only 30% patients over 7.5% [58.5 mmol/mol]) could also have contributed to this result.

Little is known regarding the relationship between functional and structural abnormalities in the setting of diabetes-induced retinal neurodegeneration. In the present study we have found an impairment of the retinal function in the initial stages of retinal disease in type 2 diabetic patients with a good correspondence between central mfERG changes (3 central rings) and SD-

OCT structural damage (thinning of GCL-IPL and RNFL layers), which increased with the progression of DR.

It is worth mentioning that 32% of the patients with visible microvascular disease in color fundus photography (ETDRS 20-35) did not present any functional or structural abnormality related to neurodegeneration. This finding suggests the presence of a significant proportion of patients with a primarily microvascular or microangiopathic phenotype, in which the role of neurodegeneration remains to be elucidated. On the other hand 61% of the patients without visible microvascular disease (ETDRS<20) presented abnormalities related to neurodegeneration assessed by either mfERG or SD-OCT, thus suggesting the presence of a neurodysfunctional or neurodegenerative phenotype. Prospective follow up will determine whether this phenotype will be more prone to develop microvascular disease than in those patients without neurodegenerative abnormalities. The identification of these two phenotypes is an important issue because of its therapeutic implications, particularly when analyzing the potential effect of neuroprotective agents.

In conclusion, functional abnormalities can be detected by mfERG in almost 60% of type 2 diabetic patients with no apparent fundus abnormalities and these changes antedate the structural damage measured by SD-OCT. However, this is not a universal pattern and in a significant proportion of type 2 diabetic patients the development of microvascular disease is not preceded by any abnormality in neurodegeneration measurements used in this study (SD-OCT and mfERG). Overall our findings open up the hypothesis that neurodegeneration could play a role in the pathogenesis of DR in a large proportion, but not in all type 2 diabetic patients.

## **Acknowledgments**

This project has received funding from the European Union's Seventh Framework Programme for research, technological development and demonstration under grant agreement No. 278040.

## **Duality of Interest**

No potential conflicts of interest relevant to this article were reported.

## **Author Contributions**

A.R.S. researched data and wrote and edited the manuscript. L.R., F.B., R.L., C.E., U.F., J.G.A., J. Gi., J.Gr., S.P.H., G.E.L., P.M., E.M., P.S., S.A., S.S., C.S., M.P., and B.P researched data, contributed to the discussion and reviewed the manuscript . M.A.C, and C.H. analyzed the data, contributed to the discussion and reviewed/edited the manuscript. J.C.V., and R.S. contributed to the study design, discussion, reviewed the manuscript and are the guarantors of this work and, as such, had full access to all the data in the study and take responsibility for the integrity of the data and the accuracy of the data analysis.

## REFERENCES

1. Yau JW, Rogers SL, Kawasaki R, Lamoureux EL, Kowalski JW, Bek T, Chen SJ, Dekker JM, Fletcher A, Grauslund J, Haffner S, Hamman RF, Ikram MK, Kayama T, Klein BE, Klein R, Krishnaiah S, Mayurasakorn K, O'Hare JP, Orchard TJ, Porta M, Rema M, Roy MS, Sharma T, Shaw J, Taylor H, Tielsch JM, Varma R, Wang JJ, Wang N, West S, Xu L, Yasuda M, Zhang X, Mitchell P, Wong TY; Meta-Analysis for Eye Disease (META-EYE) Study Group. Meta-Analysis for Eye Disease (META-EYE) Study Group. Global prevalence and major risk factors of diabetic retinopathy. *Diabetes Care* 2012;35:556-564
2. Guariguata L, Nolan T, Beagley J, Linnenkamp U, Jacqmain O. International Diabetes Federation. *Diabetes Atlas*. International Diabetes Federation 2014, Brussels, Belgium.
3. Simó R, Hernández C. Novel approaches for treating diabetic retinopathy based on recent pathogenic evidence. *Prog Retin Eye Res* 2015;48:160-180
4. Stitt AW, Curtis TM, Chen M, Medina RJ, McKay GJ, Jenkins A, Gardiner TA, Lyons TJ, Hammes HP, Simó R, Lois N. The progress in understanding and treatment of diabetic retinopathy. *Prog Retin Eye Res* 2016;51:156-186.
5. Antonetti DA, Klein R, Gardner TW. Diabetic retinopathy. *N Engl J Med* 2012;366:1227-1239
6. Simó R, Hernández C, European Consortium for the Early Treatment of Diabetic Retinopathy (EUROCONDOR). Neurodegeneration is an early event in diabetic retinopathy, therapeutic implications. *Br J Ophthalmol* 2012; 96:1285-1290
7. Abcouwer SF, Gardner TW. Diabetic retinopathy: loss of neuroretinal adaptation to the diabetic metabolic environment. *Ann N Y Acad Sci* 2014;1311:174-190
8. Simó R, Hernández C. European Consortium for the Early Treatment of Diabetic Retinopathy (EUROCONDOR). Neurodegeneration in the diabetic eye, new insights and therapeutic perspectives. *Trends Endocrinol Metab* 2014;25:23-33

9. Hernández C, García-Ramírez M, Corraliza L, Fernández-Carneado J, Farrera-Sinfreu J, Ponsati B, González-Rodríguez A, Valverde AM, Simó R.. Topical administration of somatostatin prevents retinal neurodegeneration in experimental diabetes. *Diabetes* 2013;62:2569-2578
10. Hernández C, Bogdanov P, Corraliza L, García-Ramírez M, Solà-Adell C, Arranz JA, Arroba AI, Valverde AM, Simó R. Topical administration of GLP-1 receptor agonists prevents retinal neurodegeneration in experimental diabetes. *Diabetes* 2016;65:172-187
11. Reis A, Mateus C, Melo P, Figueira J, Cunha-Vaz J, Castelo-Branco M. Neuroretinal dysfunction with intact blood-retinal barrier and absent vasculopathy in type 1 diabetes. *Diabetes* 2014;63:3926-3937
12. Han Y, Schneck ME, Bearnse MA, Barez S, Jacobsen CH, Jewell NP, Adams AJ. Formulation and evaluation of a predictive model to identify the sites of future diabetic retinopathy. *Invest Ophthalmol Vis Sci* 2004;45:4106-4112
13. Harrison WW, Bearnse MA Jr., Ng JS, Jewell NP, Barez S, Burger D, Schneck ME, Adams AJ. Multifocal electroretinograms predict onset of diabetic retinopathy in adult patients with diabetes. *Invest Ophthalmol Vis Sci* 2011; 52:772-777
14. Ng JS, Bearnse MA Jr., Schneck ME, Barez S, Adams AJ. Local diabetic retinopathy prediction by multifocal ERG delays over 3 years. *Invest Ophthalmol Vis Sci* 2008;49:1622-1628
15. Marmor MF, Fulton AB, Holder GE, Miyake Y, Brigell M, Bach M; International Society for Clinical Electrophysiology of Vision. ISCEV Standard for full-field clinical electroretinography (2008 update). *Doc Ophthalmol* 2009; 118:69–77
16. Lakhani E, Wright T, Abdoell M, Westall C. Multifocal ERG defects associated with insufficient long-term glycemic control in adolescents with type 1 diabetes. *Invest Ophthalmol Vis Sci* 2010;51:5297-5303



17. Simão S, Costa M.A, Cunha-Vaz J, Simó R; European Consortium for the Early Treatment of Diabetic Retinopathy (EUROCONDOR). Development of a Normative Database for Multifocal Electroretinography in the Context of a Multicenter Clinical Trial. *Ophthalmic Res* 2017;57:107-117
18. Frydkjaer-Olsen U, Soegaard Hansen R, Simó R, Cunha-Vaz J, Peto T, Grauslund J; EUROCONDOR. Correlation between Retinal Vessel Calibre and Neurodegeneration in Patients with Type 2 Diabetes Mellitus in the European Consortium for the Early Treatment of Diabetic Retinopathy (EUROCONDOR). *Ophthalmic Res* 2016;56:10-16
19. Nagatomo A, Nao-i N, Maruiwa F, Arai M, Sawade A. Multifocal Electroretinograms in Normal Subjects. *Jpn J Ophthalmol* 1998;42:129-135
20. Azad R, Ghatak U, Sharma YR, Chandra P. Multifocal Electroretinogram in Normal Emmetropic Subjects: Correction with Optical Coherence Tomography. *Indian J Ophthalmol* 2012;60:49-52
21. Curcio CA, Slan KR Jr, Packer O, Hendrickon AE, Kalina RE. Distribution of cones in human and monkey retina: Individual variability and radial asymmetry. *Science* 1987;236:579-582
22. Curcio CA, Sloan KR, Kalina RE, Hendrickson AE. Human photoreceptor topography. *J Comp Neurol* 1990;292:497-523
23. Bandello F, Tejerina AN, Vujosevic S, Varano M, Egan C, Sivaprasad S, Menon G, Massin P, Verbraak FD, Lund-Andersen H, Martinez JP, Jürgens I, Smets RM, Coriat C, Wiedemann P, Ágoas V, Querques G, Holz FG, Nunes S, Alves D, Neves C, Santos T, Ribeiro L, Cunha-Vaz J; EVICR.net: Retinal Layer Location of Increased Retinal Thickness in Eyes with

## **Supplemental Material**

### mfERG standardization

Consistency of outcomes across multiple testing site was ensured through appropriate training and consistent monitoring of mfERG outcomes to maintain quality assurance standards. In order to ensure appropriate quality of participation an acquisition protocol was created and all clinical sites used the same equipment (RETI-port/scan21 – Roland Consult) set up with fixed acquisition parameters. At least one technician from all 11 sites received specialized training at Coimbra Ophthalmology Reading Centre to learn the acquisition protocol and to ensure consistency of the examination technique. In addition, all sites received individualized on-site refresher training following specialized training. Before acquiring any EUROCONDOR study exams, each technician performed four mfERG examinations (four eyes) according to the acquisition protocol that was reviewed by CORC to ensure quality exams and certify the technicians.